



Horbury Dental

care & implant clinic

making you smile for over 75 years

James Hudson

BDS, MSc Clin Perio, Dip Imp Dent RCS (uk)

Implant Referral Dentist



James graduated from Turner Dental Hospital, Manchester in 1995. Returning to Yorkshire he quickly established himself as principal dentist of his

own practice in Sheffield. During this period he had roles as 'Area Clinical Manager' for ADP Dental, Foundation Dentist Trainer over 6 separate years and clinical demonstrator of Restorative Dentistry at The Charles Clifford Dental Hospital.

After gaining his MSc in Clinical Periodontology at UCLan (2013) James has been involved in training qualified dentists locally in Periodontal treatment techniques.

He subsequently gained his Diploma in Dental Implantology (UK) from the prestigious Royal College of Surgeons in 2016. He has amassed a huge amount of experience in treating all aspects of gum and implant treatments including immediate implants, bone and soft tissue grafting, sinus taps and sinus lifts. He particularly enjoys helping patients to complete treatment plans that will make their mouths healthier and long term more stable. Improving their ability to function better and have more confidence in their appearance.

James is registered with the General Dental Council (GDC) (70818) and he is a full member of the British Society of Periodontology (BSP) and Association of Dental Implantology (ADI).

Treatments provided:

Dental Implants

Sinus grafts / taps

Immediate implants

Bone augmentation

Gum augmentation

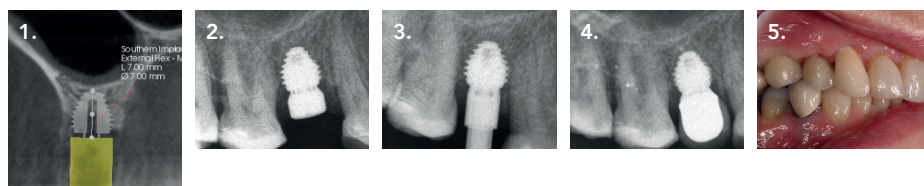
PRF

IV sedation with midazolam

Example Cases

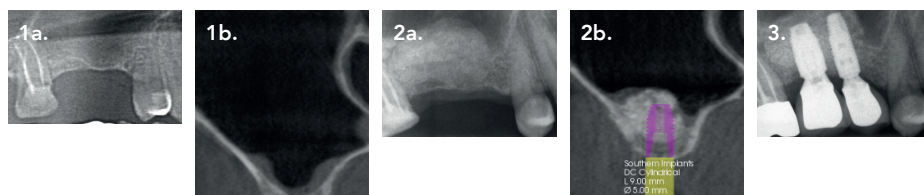
Southern Implant MAX case. Available ridge was wide and low. Use of a 6 mm diam x 7mm height, ex-hex, allowed for excellent primary stability and a wide prosthetic platform giving good aesthetics and good emergence angles for final crown.

1. Pre-surgery planning CBCT cross sectional slice at 15 region.
2. Implant placed and healing abutment.
3. Impression coping verification Xray to confirm full seating of ex hex connection
4. Final screw retained crown in situ
5. Final crown at time of restoration



Sinus graft lift to facilitate dental implant treatment to replace 15 and 16 using Southern DCC implants.

- 1a & b. X ray and CBCT images of sinus demonstrating minimal remaining alveolar bone with healthy sinus lining.
- 2a & b. X ray and CBCT following lateral wall sinus grafting demonstrating good volume of internal sinus graft and healthy sinus lining. Planning of site for subsequent DCC 5mm x 9mm implant at 16 and 4mm x 11mm at 15 sites.
3. Final screw retained crowns in position.



✉ willings@horburydentalcare.co.uk

☎ 01924 211 234

🌐 horburydentalcare.co.uk



Follow us on facebook,
twitter and Instagram