



Horbury Dental

care & implant clinic

making you smile for over 75 years

Mark Willings

BDS MFGDP (UK) DIP IMP DENT RCS (ENG) FFGDP (UK)

Dental Implant & Full Mouth Rehabilitation Dentist



After graduating from Guy's Hospital in 1991, Mark worked in associate positions in Kent and Surrey before returning home to his native Yorkshire.

Mark gained membership of the Faculty of General Dental Practice (FGDP) in 1998 and has completed the diploma in implant dentistry at the Royal College of Surgeons of England and was awarded the Advanced Certificate. In 2007, he was awarded fellowship of the FGDP at the Royal College of Surgeons of England. Mark's focus has been exclusively in implant dentistry and he worked in the University Dental Hospital of Manchester for 10 years, where he gained

experience treating very advanced cases for rehabilitation after cancer surgery. Mark has also held posts in postgraduate dental education at the University of Leeds, University of Manchester and The Royal College of Surgeons of England.

Mark lectures nationally on the use of dental implants for simple and complex rehabilitations and to maintain knowledge, he attends conferences and training courses all over the world.

Mark has acted as a key opinion leader for several implant companies and was on the founding board for Astra to deliver the highest levels of dental implant teaching for dentists. He published articles on implant dentistry and research during his time at Manchester where he was involved in the Cochrane collaboration.

Treatments provided:

Dental Implants

Sinus lifts

Immediate Implants

Bone augmentation procedures and PRF

Same day teeth with dental implants

IV sedation with Midazola

Example Cases

At HDC we have a huge wealth of knowledge and experience. Mark has been involved with implants for 30 years and good depth of knowledge with many implant systems.

This helps when we see cases with problems. We are happy to present the following case to explain how we may be able to help.

This patient had her implant treatment carried out 20 years ago in York. The dentist has now retired and she has had implant loss due to peri-implantitis.

Originally, she was reconstructed with a magnet retained over denture.

Subsequently she was converted to a locator over denture system.

The patient hated the removable restoration and ideally wanted a fixed reconstruction but lost the distal implant in the upper left quadrant.

She was referred to me by her new implant dentist who was uncertain how to manage her case which involved different (and now historic implant systems).

And with implants at unfavourable angulations and positions - remember this was originally done for a magnet retained over denture.

The original implants are Brenemark type 2 External hex implants.

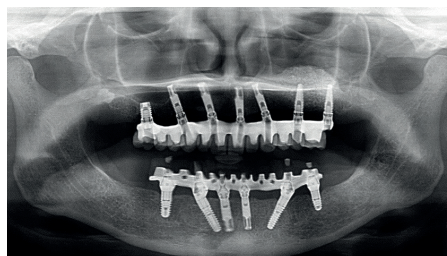
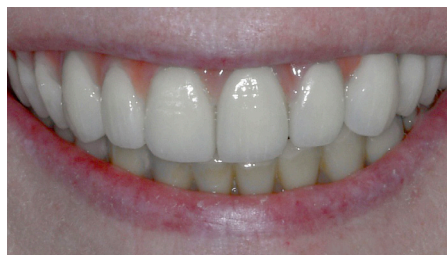I treated her lower jaw 6 years ago placing Bredent implants and linking these to 2 existing Branemark implants in the anterior mandible.

After this has proven successful, the patient was desperate to undergo treatment in the upper jaw.

I have carried out sinus augmentation and placement of 2 additional southern external hex implants in the ULQ.

The technical challenges of implant position and angulation has been overcome with modern technology.

We have used angle correction screws and a milled Titanium framework with individual E-max crowns bonded in situ.



✉ willings@horburydentalcare.co.uk

☎ 01924 211 234

🌐 horburydentalcare.co.uk



Follow us on facebook,
twitter and Instagram