



Horbury Dental
care & implant clinic

making you smile for over 75 years

AUTUMN
2022

THE HDC CURRY CLUB

I am delighted to report that on Wednesday 14th September, Horbury Dentalcare hosted the first Curry Club at Beaumont Ceramics in Birstall.

The event was an enormous success with a full house attending for an evening of lectures followed by a great curry cooked by "Spicy Biker".

The feedback we have had is off the scale with so many positive comments about the structure of the evening, the quality of the presentations and the food!

There is a real enthusiasm to make this a regular club meeting and I am delighted to give information in the newsletter of forthcoming plans and meeting dates.

Places are strictly limited. All curry club members have received invitations to the next meeting on Weds 30th November. Please book your place promptly.

If you are not yet a study club member, please contact us now to join and reserve your place to be part of this exciting new venture. The concept is to learn and grow our skills together in a non judgemental environment. To share our experiences peer to peer, and to network with our local profession in a fun relaxed environment over a beer and a curry.

I look forwards to seeing you at the next meeting which promises to be another great evening. Please book now to avoid disappointment - unfortunately places are strictly limited by numbers we can host at the venue.

Mark Willings

BDS MFGDP (UK) DIP IMP DENT RCS (ENG) FFGDP (UK)



November 30th CONTEMPORARY AESTHETIC DENTISTRY

Components of a beautiful smile (**Francois Vannerem**)

Anterior Immediate Implants - the gold standard for aesthetic implant dentistry INVERTA implants - (**James Hudson**)

January 25th OCCLUSION PART 1

The need for posterior support (**Tom Rawlins**)

Immediate posterior implant treatment - THE MAX - (**Nick Lane**)

April 26th OCCLUSION PART 2

Managing complex / advanced wear cases (**Tom Rawlins**)

Implant options for the failed dentition (**Mark Willings**)

June 14th DIGITAL DENTISTRY PART 1

CT scans in Endodontics (**Tom Willan**)

Implant planning with interactive software (**Mark Willings**)



CASE STUDY

AESTHETICS @ HORBURY DENTAL CARE



Minimal Prep Emax Veneers

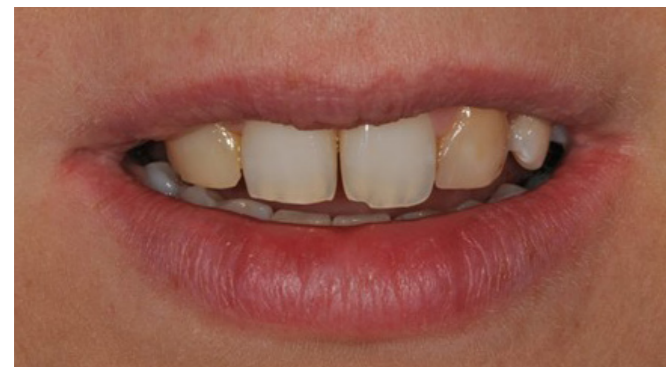This 31-year-old female was referred as she was unhappy with her dental appearance. She had 3 missing upper teeth (UR4 UR2 and UL2) and had already had some composite restorations to try and mask this. We removed the old composite, whitened, and carried out a 2D and additive 3D smile design with the aim of masking the underlying missing teeth and creating more symmetry. The design incorporated the upper 8 front teeth which on the upper right included the first molar. Gummy smile Botulinum Toxin was discussed and declined by the patient.

The mock-up was placed in bisacryl, modified for aesthetics and occlusion, and approved. This was then copied into 8 minimal prep E-max veneers with which the patient was delighted.

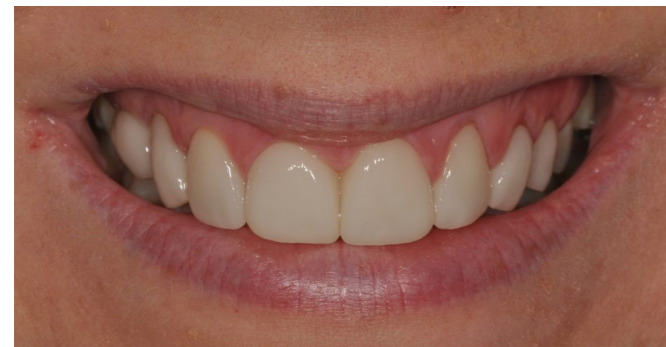Additive Composite Bonding

This patient was referred for rehabilitation after suffering from Bulimia for many years. She had developed generalised moderate tooth surface loss. There was some dentine exposure on the premolar and some molar teeth. She was treated for the Bulimia by her GP before attending for her consultation. She had had some composites placed in the past to fill wear facets and these were staining and failing aesthetically.

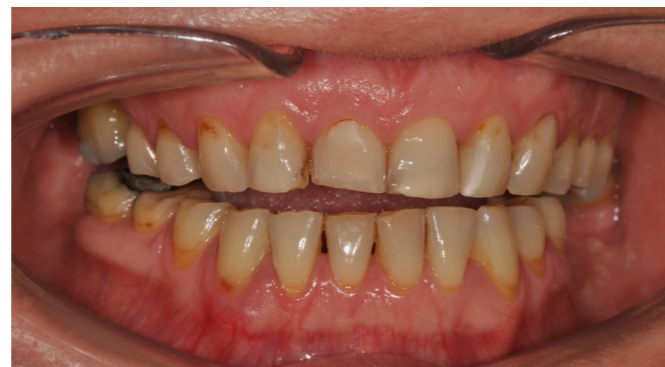We carried out a digital diagnostic wax-up of the upper and lower 6-6 at an increased OVD, whitened, and then fitted the mock-up. Occlusion and aesthetics were adjusted and approved. We then copied this into zero-prep heated injection-moulded composites at the new OVD after removing the old composite and air-abrading.



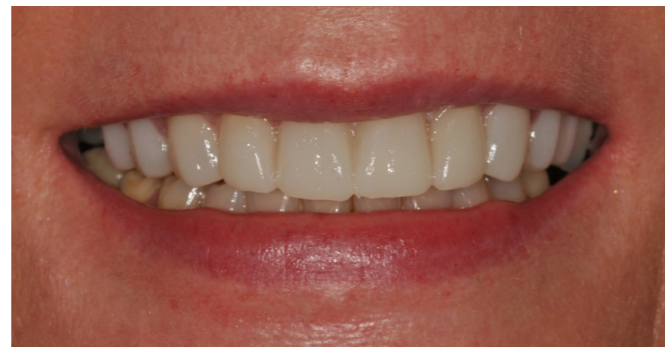BEFORE



AFTER



BEFORE



AFTER

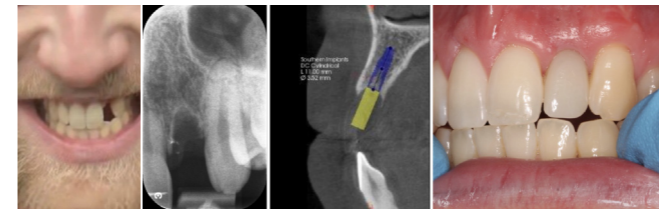


CASE STUDY

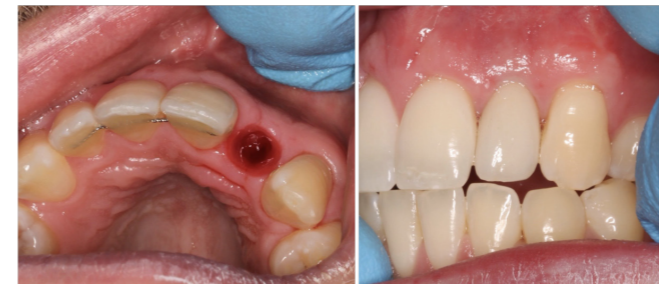
IMPLANTS @ HORBURY DENTAL CARE



Immediate co axis dental implant with immediate load crown



26 year old male, fit and well, presented with traumatic injury to mouth results in avulsion of UL2. PA shows shortened root length of upper anteriors, adequate mesio-distal width for 3.5 diameter implant with favourable occlusion. Immediate implant was planned and placed within 2 weeks of trauma. Photo shows tissues at 2 weeks post placement.

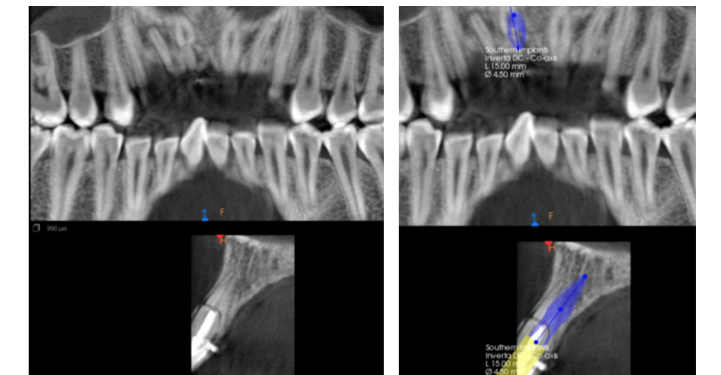


At three month review temp crown removal and impressions completed. Photos demonstrate maintained buccal contour and good, stable zenith position of UL2.

Final crown secured and good final aesthetics.

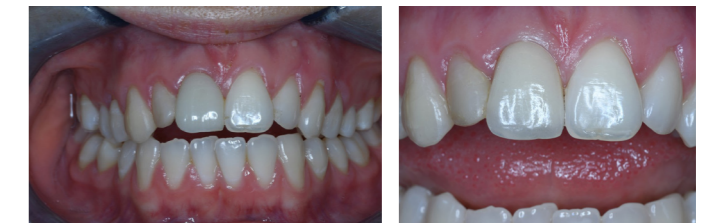Immediate INVERTA implant with immediate replacement crown

Young female patient presents with root fracture at UR1 after trauma
Planned for immediate tooth replacement at time of extraction

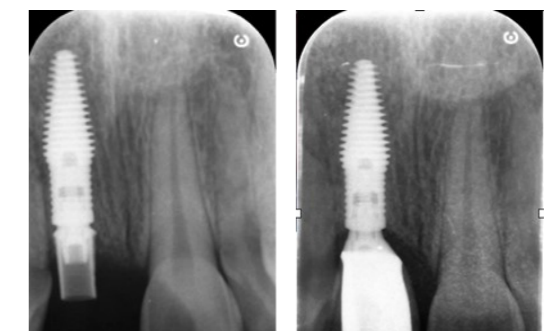


CT SCAN pre op

Pre-op planning



Definitive screw retained porcelain bonded crown



Control radiograph post placement and provisionalisation

Baseline post restoration

CURRY CLUB AND CASES

CONTEMPORARY AESTHETIC DENTISTRY

Time to talk aesthetics

The curry club is for all dentists and will cover different aspects of clinical dentistry throughout the year. At the second meeting we will be discussing components of creating a beautiful smile including the gold standard for aesthetic implant dentistry.

30th November 2022

6.45pm

Welcome from Mark Willings

6.50pm

Contemporary Aesthetic Dentistry (Francois Vannerem)

7.10pm

Anterior Immediate Implants - the gold standard for aesthetic implant dentistry (James Hudson)

8pm

Cases and Curry

How to join Curry Club:

Please email willings@horburydentalcare.co.uk or call the practice on **01924 211234** and speak to Emily Ball or Emma Ferreira.

Horbury Dental Care, Vincent House, Queen Street
Horbury, WF4 6LP



✉ willings@horburydentalcare.co.uk

☎ **01924 211 234**

🌐 horburydentalcare.co.uk



Follow us on facebook,
twitter and Instagram