



Time to talk occlusion

Wednesday 25th January 2023

Beaumont's Ceramics Lab, Birstall.

6.45pm

Welcome from Mark Willings

6.50pm

The need for posterior support (Tom Rawlins)

7.10pm

Immediate posterior implant treatment -
THE MAX - (Nick Lane)

8pm

Cases and Curry

RSVP & How to join Curry Club

Please email willings@horburydentalcare.co.uk or call the practice on **01924 211234** and speak to Emily Ball or Emma Ferreira.

Horbury Dental Care, Vincent House,
Queen Street Horbury, WF4 6LP.

✉ willings@horburydentalcare.co.uk

☎ 01924 211 234

🌐 horburydentalcare.co.uk



Follow us on facebook,
twitter and Instagram

WELCOME TO YOUR WINTER NEWSLETTER

On behalf of the whole team here at Horbury Dental Care, I would like to wish everyone a very happy and prosperous new year. We hope you had a wonderful festive period and enjoyed some time off with your loved ones.

I would like to thank you for making 2022 such a great year. Another record breaking number of referrals received. Each and every referral is gratefully received by myself and the whole team here at Horbury. We strive to provide the very best service to you and your patients; I hope we have delivered that to all of you using our services.

Emily will be out and about in the New Year. If you wish to arrange a "Lunch and Learn" for your team to hear updates on any aspects of the services we provide, then please do contact her emily.ball@horburydentalcare.co.uk. We will provide lunch for you and make a presentation which gives you all verifiable CPD and it's fun to learn as team!

On a personal note, I am thrilled to announce the birth of my first grandson, Edward Vincent Hobbah. Harriet and Jordan welcomed Ted to the world on the 11th October this year and we are incredibly proud of them all. Could Ted be the next generation to add to the existing 5 generations of dentists in the family...?

Finally, our next curry club is on Wednesday 25th January to be held at Beaumont Ceramics in Birstall. Places are strictly limited, please get in touch with the team on willings@horburydentalcare.co.uk to secure your place. This will be a fun enjoyable evening to enjoy a curry and a beer with like-minded local dentists. Sign up and become a member now!

Myself and my team are looking forward to seeing you all very soon.

Mark Willings

BDS MFGDP (UK) DIP IMP
DENT RCS (ENG) FFGDP (UK)



January 25th OCCLUSION PART 1

The need for posterior support
(Tom Rawlins)

Immediate posterior implant treatment - THE MAX -
(Nick Lane)

April 26th OCCLUSION PART 2

Managing complex / advanced wear cases
(Tom Rawlins)

Implant options for the failed dentition
(Mark Willings)

June 14th DIGITAL DENTISTRY PART 1

CT scans in Endodontics
(Tom Willan)

Implant planning with interactive software
(Mark Willings)

Wednesday 18th October DIGITAL DENTISTRY PART 2

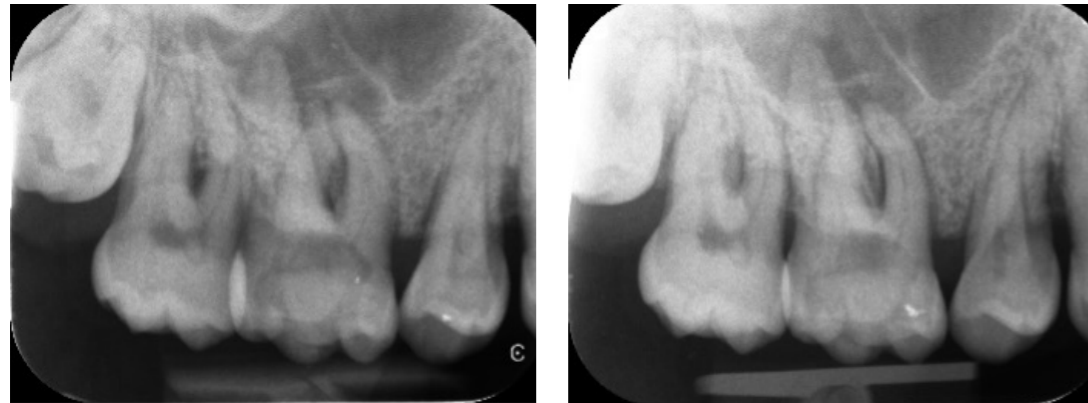
Intra oral scanning and milling
(Francois Vanerem)

The digital laboratory
(Adam Clark)



ENDODONTICS @ HORBURY DENTAL CARE

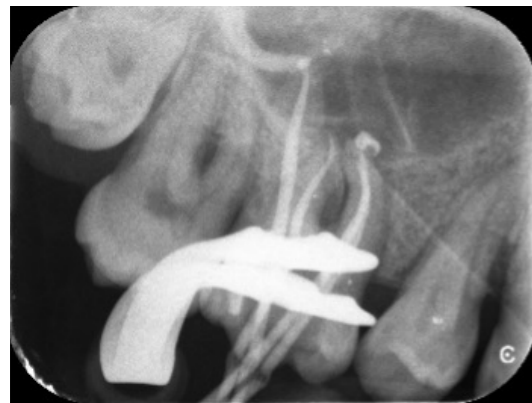Preoperative Radiographs



This patient was referred by her GDP for endodontic treatment on her UL6. Her GDP had attempted to access the tooth but unfortunately was unable to locate the buccal canals. Initial radiographic assessment showed a complex root canal anatomy with a double curvature in the distobuccal canal. The tooth was accessed under microscope magnification and 4 canals were found. The tooth was

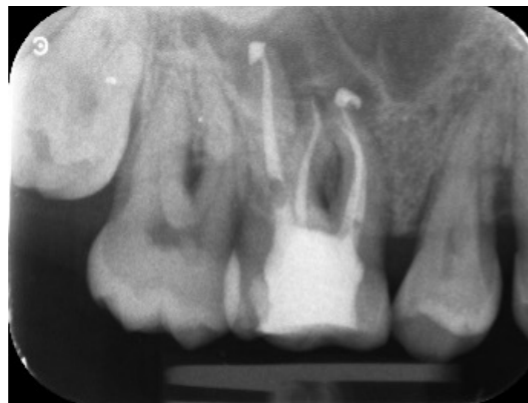
mechanically prepared with the Protaper Ultimate file system and irrigated with 2% Sodium Hypochlorite and a final soak of 17% EDTA under ultrasonic activation. The tooth was obturated with AH+ Bioceramic sealer and a composite core placed, before referring this patient back to her GDP to provide a crown for cuspal coverage.

MID-FILL RADIOGRAPH



The Post operative radiographs shows a good obturation on all four canals. The Protaper Ultimate system was advantageous in this case as the reduced file diameter allowed for preservation of pericervical dentine, while also respecting the complex root anatomy. There were sealer puffs present on the palatal and MB1 canals, which will be well tolerated by the surrounding tissue as a result of the biocompatible sealer used.

POSTOPERATIVE RADIOGRAPH



CASE STUDY




NAME:
Thomas Willan

POSITION:
Associate at
Horbury Dental Care
for 7 years.

QUALIFICATION:
Qualified in 2011.
In 2018 he
completed the
prestigious Diploma
in Restorative
Dentistry at the Royal
College of Surgeons.

SPECIAL INTEREST:
Endodontics.
Tom has recently
completed an MSc
in Endodontics
and is happy to
take referrals for
endodontic and
restorative cases at
Horbury Dental Care.



RESTORATIVE DENTISTRY @ HORBURY DENTAL CARE

This patient attended with severe tooth surface loss of his lower teeth. This was a combination of erosion and attrition. His upper arch was restored with crowns which were in reasonable condition.

He had no pain or symptoms, but had reduced vertical height and was concerned about the long term prognosis of his dentition. To make things more complicated, he would only have treatment under sedation.

Initially we took a scan of his mouth in RCP and requested a diagnostic wax up of full lower at an increased OVD of 3mm. We performed a smile trial and the patient consented to the proposed changes.

In the first sedation appointment, we restored the cores with composite and prepared all his lower teeth through a transferred index of his wax up as to be as conservative as possible. His posterior teeth were prepared for zirconia crowns and his anterior teeth were prepared for porcelain veneers. We maintained the bite by taking three sectional Futar-D recordings during the preparation phase.

In the second sedation appointment, we cemented the zirconia crowns and bonded the veneers. The occlusion was checked and it was verified at a 2 week review appointment. Finally, his LL6 was restored with a screw retained implant crown.

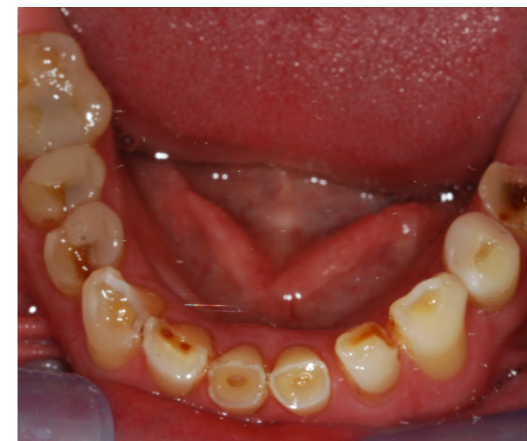

NAME:
Tom Rawlins

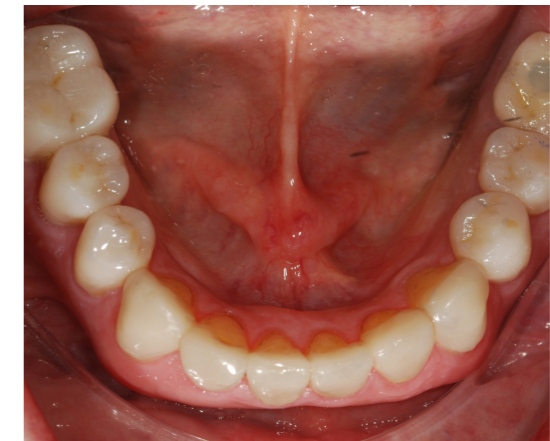POSITION:
Associate at
Horbury Dental Care
for 12 years.

QUALIFICATION:
Completed the
Restorative Diploma
at the Royal College
of Surgeons in
2016 and achieved
a distinction level
MSc qualification in
Advanced Dental
Clinical Practice
(Restorative) at the
University of Kent
in 2018.

SPECIAL INTEREST:
Restorative Dentistry
& Implantology.
Tom accepts
referrals for the
following, Full Mouth
Rehabilitations,
Severe Tooth Wear,
Aesthetic Dentistry,
Dental Implants, and
Smile Makeovers.



BEFORE



AFTER